ASTHMA ALLERGY IMMUNOLOGY
ASTIM ALLERJİ İMMÜNOLOJİ

doi: 10.21911/aai.2025.831
Asthma Allergy Immunol 2025;23:191-194

CASE REPORT

Received: 07.05.2025 • Accepted: 18.05.2025
Online Published: 05.08.2025

Extraordinary Appearance of Primary Immunodeficiency: Case Report

Yasemin AKGUL BALABAN[1], Mustafa Ilker INAN[1], Alp OKSUZ[2], Fevzi DEMIREL[1], Ozgur KARTAL[1]

[1] Division of Immunology and Allergic Diseases, Ankara Gulhane Training And Research Hospital, Ankara, Türkiye
[2] Division of Plastic Reconstructive and Aesthetic Surgery Clinic, Ankara Gulhane Training And Research Hospital, Ankara, Türkiye

Corresponding Author: Yasemin Akgul Balaban ✉ yabalaban@gmail.com

ABSTRACT

Primary immunodeficiency diseases (PIDs) are a heterogeneous group of diseases characterized by increased susceptibility to infections. Although patients frequently present with upper and lower respiratory tract infections, they may also present with severe and/or resistant infections in uncharacteristic presentations. A delay in diagnosis is common due to the perception of PIDs as rare congenital diseases, heterogeneity of the diseases, and lack of awareness. We present here a case of newly diagnosed primary immunodeficiency with necrotizing fasciitis. The patient was diagnosed with PID with unusually presenting infections. Therefore, increasing awareness and cooperation between different clinics is very important. PID should be kept in mind among the differential diagnoses during the investigation of long term, severe, recurrent/treatment resistant and unusually presenting infections. These cases should be consulted with an immunologist.

Keywords: Common variable immunodeficiency, intravenous immune globulin, Jeffrey modell foundation, necrotizing fasciitis, primary immunodeficiency

INTRODUCTION

Human inborn errors of immunity is a heterogeneous group of diseases in which 559 gene mutations have been identified to our current knowledge. Previously known as primary immunodeficiency diseases (PID), these patients have an increased susceptibility to infectious, autoimmune, autoinflammatory, allergic, and/or malignant diseases (1). The age of onset can vary from early childhood to adulthood. Delayed diagnosis due to lack of awareness is an important problem (2). From this point of view, it is very important to suspect the disease.

As the disease can affect many organ systems, the clinical manifestations vary widely (2). Although the common finding in most patients is increased sensitivity to infections, it is still a matter of debate which patients should be considered to have PID. Many studies in the literature have reported that the scale published by the Jeffrey Modell Foundation in 2003 by identifying 10 warning signs is useful in the screening and early diagnosis of PID (3). However, it has also been observed that these warning signs are not sufficient in some PID patients (4).

Necrotizing fasciitis is a rare, life-threatening soft tissue infection characterized by necrosis of the superficial muscle fascia and surrounding soft tissues, which progresses rapidly and requires emergency treatment (5,6). It usually occurs after skin injuries resulting from penetrating trauma or high-grade burns (6).

Here we report a case of PID presenting with an unusual infection.

CASE PRESENTATION

A 28-year-old male patient was hospitalized in the plastic surgery service in June 2023 due to necrotizing fasciitis that spread to the right shoulder girdle and elbow, fol-

ORCID Yasemin Akgul Balaban / 0000-0002-5654-1397, Mustafa Ilker Inan / 0000-0002-7984-450X, Alp Oksuz / 0009-0004-6425-0727, Fevzi Demirel / 0000-0002-9711-6821, Ozgur Kartal / 0000-0002-6666-581X

Copyright © 2025 The Author(s). This is an open-access article published by Turkish National Society of Allergy and Clinical Immunology under the terms of the Creative Commons Attribution License (CC BY NC) which permits unrestricted use, distribution, and reproduction in any medium or format, provided the original work is properly cited. No use, distribution or reproduction is permitted which does not comply with these terms.

lowed by the development of an open wound without any history of trauma after drainage of an abscess on his right arm, and was consulted in July 2023 for possible PID. He had only a history of penicillin allergy. There was no other chronic disease like diabetes mellitus and no family history of immunodeficiency, autoimmunity, cancer, or allergy. A thorough evaluation was performed to assess immunosuppressive medications and infections that could lead to secondary immunodeficiency. There was no history of drug use that could cause immunosuppression (e.g. steroids, antiepileptics, immunosuppressive drugs...). There was no IV drug use or alcohol use. The tests performed for infectious causes such as cytomegalovirus, syphilis, toxoplasma, rubella, Epstein-Barr virus, herpes, brucella, chlamydia, mumps, parvovirus, hepatitis B virus, hepatitis C virus, human immunodeficiency virus, and tuberculosis. All were negative. There was no defect related to isohemagglutinin titers. Low immunoglobulin (IG) levels were detected in the immune panel examination, which showed IGG: 373 (700-1600 mg/dl), IGM: 16.4 (40-230 mg/dl), and IGA: 30 (70-400 mg/dl). In the lymphocyte subgroup examination, we found CD56: 11.52% (6-29), CD4: 26.96% (34-63.8), CD8: 49.19% (19-48), CD19: 1.11% (7-23), CD3:79.34% (62.8-85), and CD16:11.52% (6-29). The patient was admitted with common variable immunodeficiency (CVID) in his current condition. Treatment with 600 mg/kg intravenous immunoglobulin (IVIG) was started. He received only one course of IVIG and did not come for regular follow-ups afterwards. The immunoglobulin levels had significantly increased two months after IVIG treatment and his clinical condition improved dramatically (Table I, Figure 1). Written informed consent has been obtained from the patient for the use of the images.

DISCUSSION

Necrotizing fasciitis is a rare, rapidly progressive disease that causes widespread necrosis of subcutaneous tissue and fascia. It can be highly lethal if not diagnosed early (5,6).

It is a known fact that PID is characterized by recurrent and/or severe infections (1). Patients frequently present with upper and/or lower respiratory tract infections such as sinusitis, otitis, pneumonia; diarrhea, inflammatory bowel diseases or genitourinary tract infections. In addition to infectious complications, non-infectious complications such as malignancy and autoimmune disorders can also occur in these patients (7). In a retrospective multicenter study conducted in Europe in 2014, data of 2212 patients with CVID were described and it was found that pneumonia was observed in 32% of patients, autoimmunity in 29%, splenomegaly in 26%, bronchiectasis in 23%, gastrointestinal disease in 9%, multisystem granulomas in 9%, malignancy in 5%, and lymphoma in 3% (8).

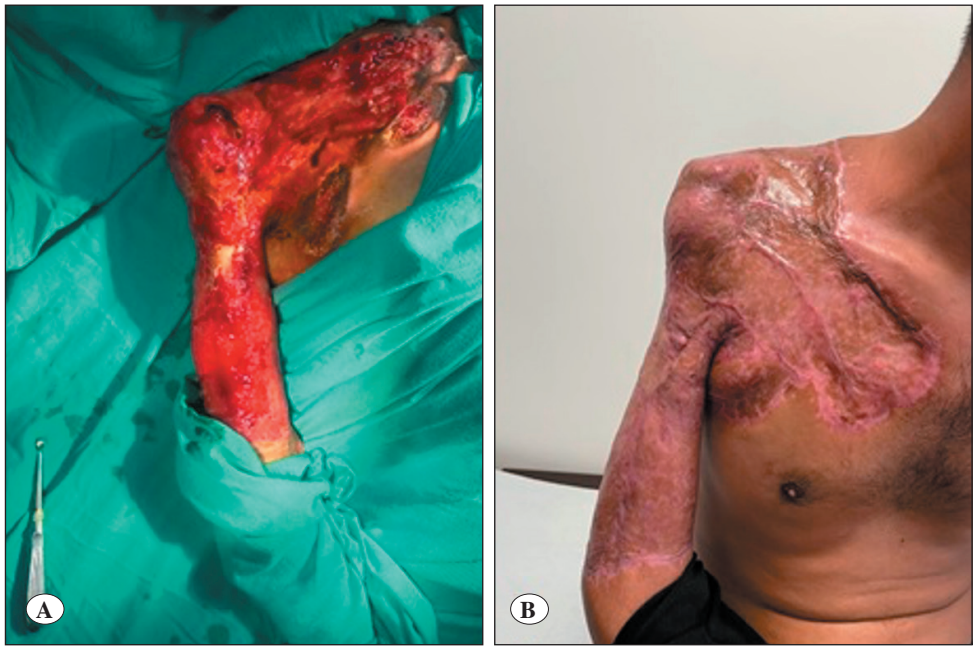

Figure 1: Condition of the wound on the patient's right shoulder before and after treatment. A remarkable improvement was achieved with a single dose of intravenous immunoglobulin treatment. **A)** during operation – before intravenous immunoglobulin. **B)** two months after intravenous immunoglobulin.

Table I: Immunoglobulin levels of the patient

	12.07.2023	29.9.2023 *	Reference Range
IGG	373	1196	700-1600 mg/dl
IGM	16.4	27.6	40-230 mg/dl
IGA	30	38.3	70-400 mg/dl
IGE	357	34.9	0-87 IU/ml
IGG1	2.98	8.01	4.05-10.11 g/l
IGG2	0.91	3.05	1.69-7.86 g/l
IGG3	0.21	0.38	0.11-0.85 g/l
IGG4	0.229	0.571	0.03-2.01 g/l

*two months after intravenous immunoglobulin treatment; **IG,** immunoglobulin

A delay in diagnosis is common due to the perception of PIDs as rare congenital diseases, the heterogeneity of the diseases, and the lack of awareness (8). This leads to increased morbidity and mortality (9). PID patients mostly need lifelong immunoglobulin replacement therapy. This can be administered intravenously or subcutaneously. Many studies have proven that this treatment improves the quality of life, improves disease severity, and slows the progression of complications (10). Therefore, early diagnosis plays a crucial role in the management of PID patients.

To the best of our knowledge, a few cases with X-linked agammaglobulinemia and hyper IgE syndrome in the pediatric age group with necrotizing fasciitis have been reported in the literature (3,4). This is the first case reported in an adult PID patient who presented with necrotizing fasciitis. Another important aspect of our case is that our patient reached adulthood without having any clinical symptoms in accordance with the Jeffrey Modell scale and any complications related to immunodeficiency such as autoimmunity or allergy or malignancy.

Low immunoglobulin levels may be seen in necrotizing fasciitis due to extensive tissue destruction and systemic inflammation (11). It is therefore appropriate to evaluate the patient in detail in terms of potential causes of secondary immunodeficiency before considering the diagnosis of primary immunodeficiency. The patient had no history of immunosuppressive drugs or infections known to cause secondary immunodeficiency. There was no evidence of protein-losing enteropathy, nephropathy, or burns. Nutritional status was adequate, with no history of malnutrition or significant weight loss in the last 9-10 years. Albumin levels were within the normal range. The development of necrotizing fasciitis in a patient with no prior health issues other than a penicillin allergy and no history of trauma strongly raised the suspicion of an underlying primary immunodeficiency. He did not have a positive family history of PID. He also developed necrotizing fasciitis without any trauma. He was diagnosed with PID following this unusual presentation of infection. Therefore, increasing awareness and cooperation between other clinics is a very important.

In this case report, we present a striking and rare clinical manifestation of primary immunodeficiency (PID) with necrotizing fasciitis as the initial presentation in an adult patient. We think that this case is very interesting and valuable for the literature, particularly in highlighting the importance of clinical suspicion in atypical infections and the need for broader awareness of PID beyond childhood presentations. PID should be kept in mind among the differential diagnoses during the investigation of long term, severe, recurrent/treatment resistant and unusually presenting infections. These cases should be consulted with an immunologist.

Acknowledgments

None.

Conflict of Interest

The authors declare that they have no conflict of interest.

Funding

The authors received no funding for this article.

Author Contributions

Concept: **Yasemin Akgul Balaban, Fevzi Demirel,** Design: **Yasemin Akgul Balaban, Fevzi Demirel,** Data collection or processing: **Yasemin Akgul Balaban, Mustafa Ilker Inan, Alp Oksuz,** Analysis or Interpretation: **Yasemin Akgul Balaban, Mustafa Ilker Inan, Alp Oksuz,** Literature search: **Yasemin Akgul Balaban,** Writing: **Yasemin Akgul Balaban, Mustafa Ilker Inan,** Approval: **Ozgur Kartal, Fevzi Demirel.**

REFERENCES

1. Bousfiha AA, Jeddane L, Moundir A, Poli MC, Aksentijevich I, Cunningham-Rundles C, et al. The 2024 update of the IUIS phenotypic classification of human inborn errors of immunity. J Hum Immunol 2025;1(1):e20250002.
2. Mertowska P, Smolak K, Mertowski S, Grywalska E. Unraveling the Role of Toll-like Receptors in the Immunopathogenesis of Selected Primary and Secondary Immunodeficiencies. Cells 2023;12(16):2055.
3. Ten warning signs of primary immunodeficiencies [Internet]. Jeffrey Modell Foundation. Available from: http:// www.info4pi.org, [Accessed May 07, 2025]
4. Aydoğmuş Ç, Öztürk E, Çipe F, Babayiğit Hocaoğlu A, Şiraneci R. Primer İmmun Yetersizliklerin Tanısında Farkındalığı Arttıracak Klinik Özelliklerin Değerlendirilmesi. Journal of Child 2017;17(2):67-71.
5. Khamnuan P, Chuayunan N, Duangjai A, Saokaew S, Chaomuang N, Phisalprapa P. Novel clinical risk scoring model for predicting mortality in patients with necrotizing fasciitis: The MNF scoring system. Medicine (Baltimore) 2021;100(51):e28219.
6. Sablone S, Lagouvardou E, Cazzato G, Carravetta F, Maselli R, Merlanti F, et al. Necrotizing Fasciitis of the Thigh as Unusual Colonoscopic Polypectomy Complication: Review of the Literature with Case Presentation. Medicina (Kaunas) 2022;58(1):131.
7. Gupta S, Pattanaik D, Krishnaswamy G. Common Variable Immune Deficiency and Associated Complications. Chest 2019;156(3):579-93.
8. Gathmann B, Mahlaoui N, CEREDIH; Gérard L, Oksenhendler E, Warnatz K, et al. Clinical picture and treatment of 2212 patients with common variable immunodeficiency. J Allergy Clin Immunol 2014;134(1):116-26.
9. Odnoletkova I, Kindle G, Quinti I, Grimbacher B, Knerr V, Gathmann B, et al. The burden of common variable immunodeficiency disorders: A retrospective analysis of the European Society for Immunodeficiency (ESID) registry data. Orphanet J Rare Dis 2018;13(1):201.
10. Ameratunga R, Woon ST, Gillis D, Koopmans W, Steele R. New diagnostic criteria for common variable immune deficiency (CVID), which may assist with decisions to treat with intravenous or subcutaneous immunoglobulin. Clin Exp Immunol 2013;174(2):203-11.
11. Guliyeva G, Huayllani MT, Sharma NT, Janis JE. Practical Review of Necrotizing Fasciitis: Principles and Evidence-based Management. Plast Reconstr Surg Glob Open 2024;12(1):e5533.